

## Patient Information

Age

54

## Disease information

<b>psoriasis type</b>	Psoriasis Vulgaris
<b>presence + severity</b>	Very Severe
<b>percentage Body cover</b>	All the over the body
<b>The disease exists</b>	2 Years
<b>Causes disease</b>	Unknown
<b>Genetic? Then Who has the more Family</b>	No

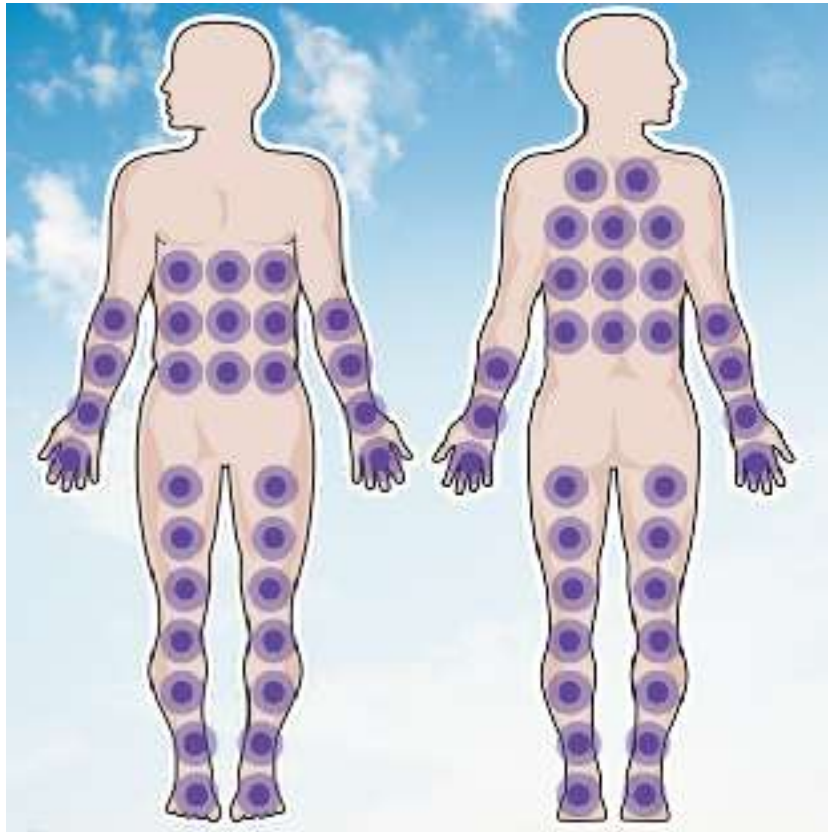
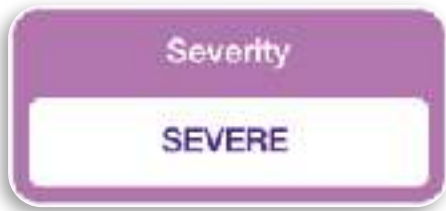## Psoriasis Area

**0 (Absent), 1 (Slight), 2 (Moderate), 3 (Severe), 4 (Very Severe)**

<b>Armpit</b>	Severe
<b>Arms</b>	Severe
<b>Elbows</b>	Severe
<b>Hands</b>	Severe
<b>Nails</b>	Severe
<b>Knees</b>	Severe
<b>Legs</b>	Severe
<b>feet</b>	Severe

## Proper Treatment

<b>The extent to which the patient followed treatment guideline</b>	Good
<b>Level of Use</b>	Very High
<b>General Feeling</b>	Very Good
<b>Skin Improvement</b>	Dramatic – The treatment was intense and they was a lot ointment needed.
<b>Side Effects</b>	No
<b>Continuing Care</b>	No



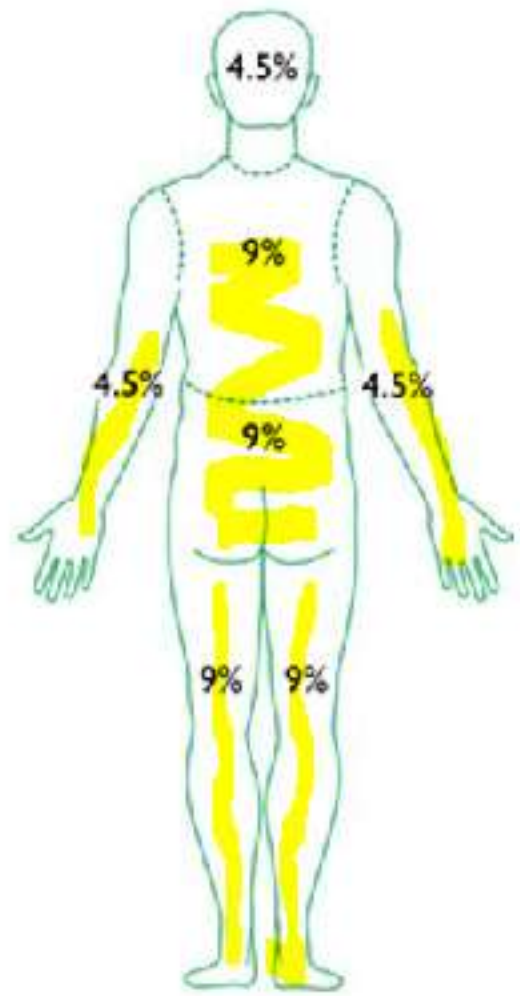
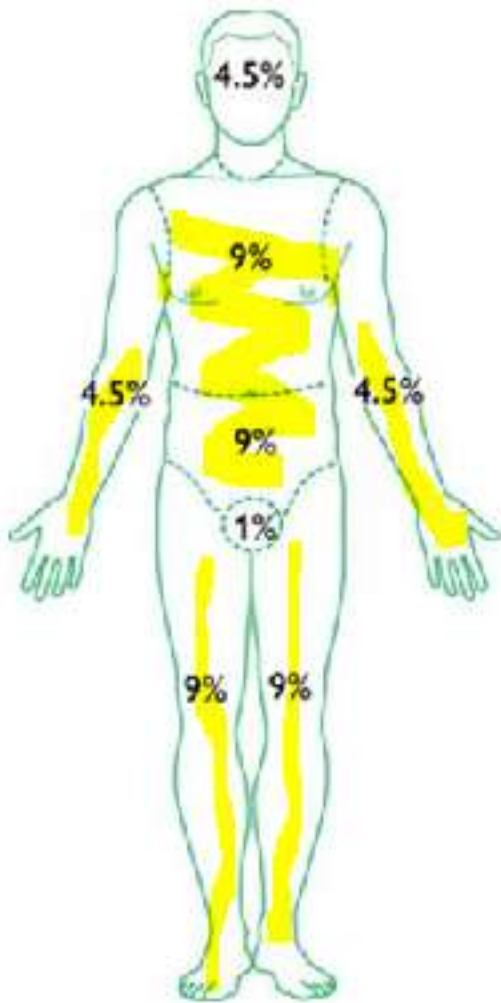
2

Nelly Kahlon	week 0	week 1	week 2	week 3	week 4	week 5	week 6
ITCHING & SCRATCHING	5	2	0	0	0	0	0
ERYTHEMA	5	4	2	1	0.5	0.5	0.5
SCALES	5	0	0	0	0	0	0
THICKNESS	5	0	0	0	0	0	0

The patient was suffering from a bad type of Psoriasis that was spreading all over the body. Full recovery was after a 2 months.

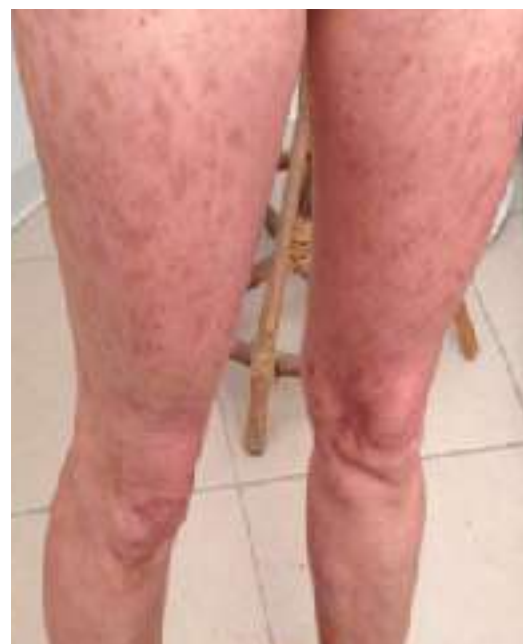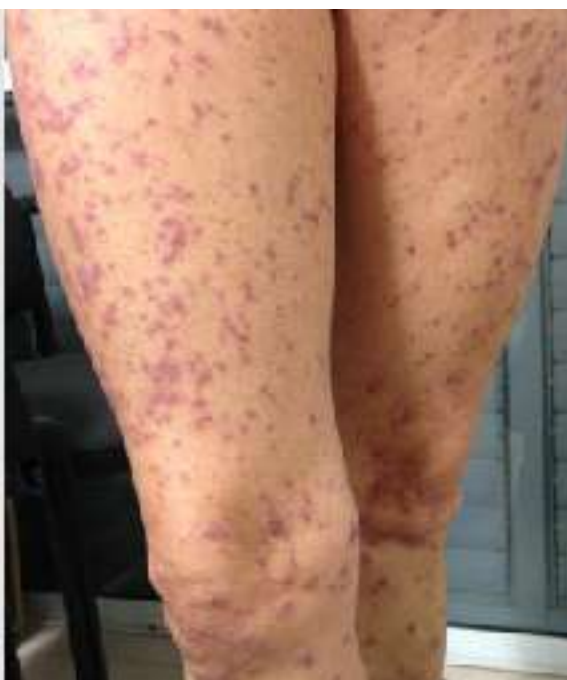The last photos shows the recovered lesions that left scars.

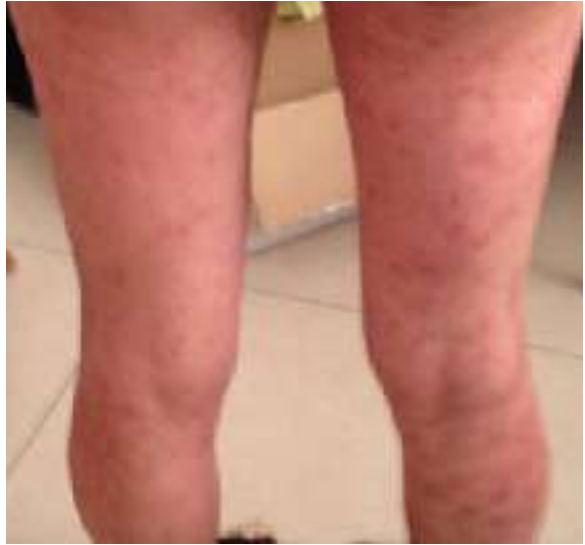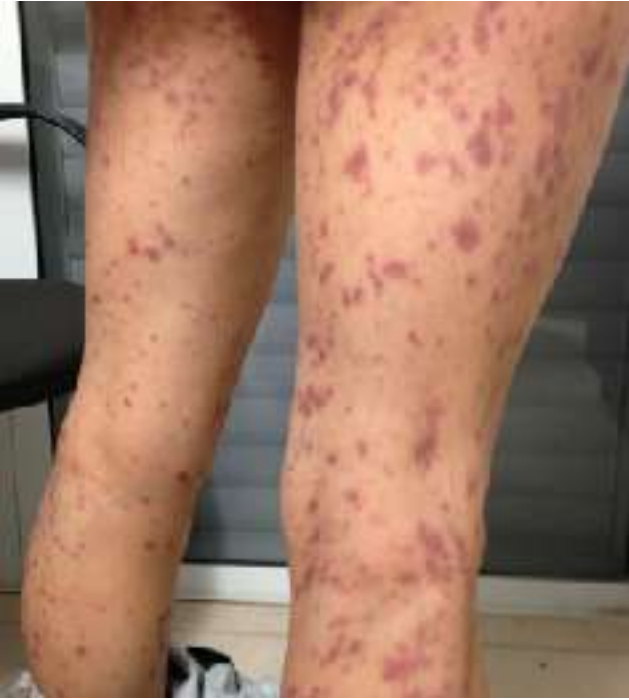The scars that remained as stains of pigmentation needed another treatment that the patient is going through these days.



3

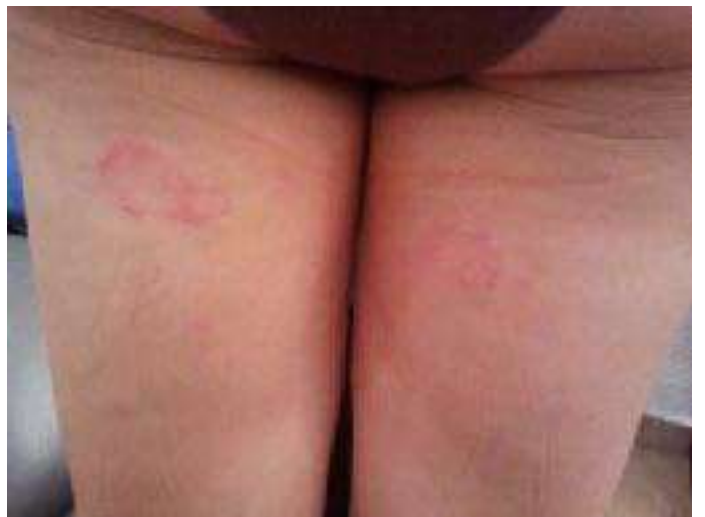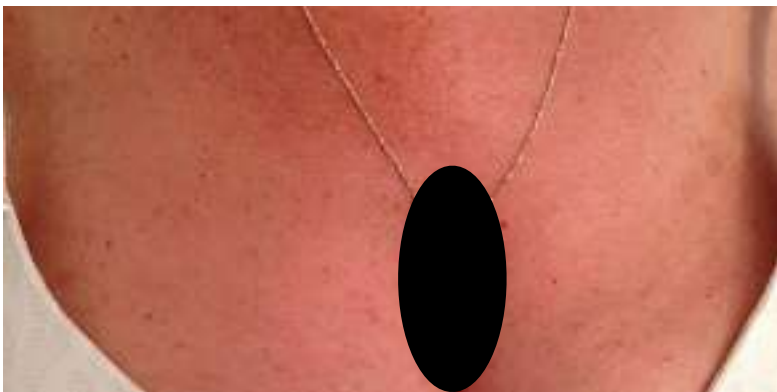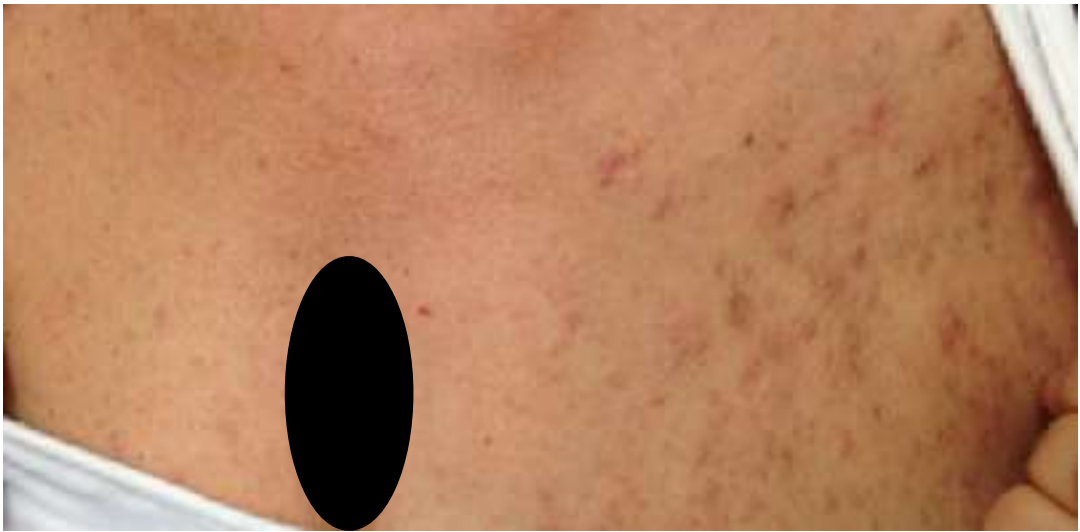**Before Using DermaZor – Week 0**



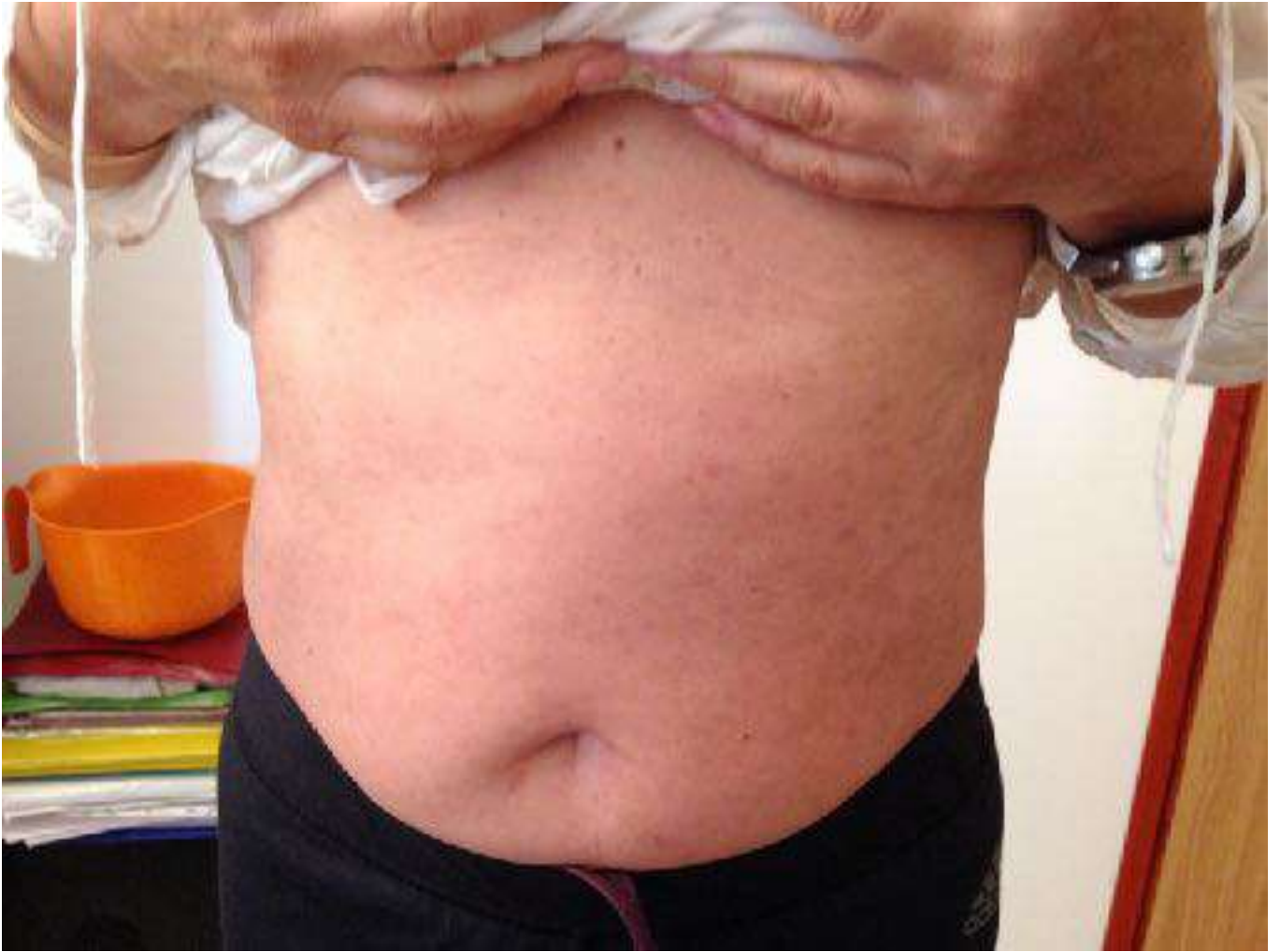

**Before Using DermaZor – Week 0**

4



5



**Before Using DermaZor – Week 0**

